

Molecular detection of Tick-Borne Pathogens in Ovaries and a Mummified Foetus of three cows with Historical Reproductive Problems in Northern Veracruz, Mexico

Detección molecular de patógenos transmitidos por garrapatas en ovarios y fetos momificados de tres vacas con historia de problemas reproductivos en el norte de Veracruz, México

Miguel Angel Lammoglia-Villagómez¹ , Amalia Cabrera-Núñez¹ , Rebeca Rojas-Ronquillo¹ , Jorge Luis Chagoya-Fuentes¹ , Ingeborg Becker² 
and Sokani Sánchez-Montes^{1,2*} 

¹Universidad Veracruzana, Facultad de Ciencias Biológicas y Agropecuarias región Tuxpan. Tuxpan de Rodríguez Cano, Veracruz, México.

²Universidad Nacional Autónoma de México, Facultad de Medicina, Unidad de Medicina Experimental, Centro de Medicina Tropical. Ciudad de México, México.

*Corresponding author: sok10108@gmail.com

ABSTRACT

The aim of this study was to identify the presence of tick-borne pathogens as the probable cause of reproductive problems in cows in a commercial dual-purpose cow operation living in tropical conditions in Northern Veracruz, Mexico. As part of the reproductive control of the herd, ultrasonography was performed periodically, and the presence of three open (non-pregnant) cows with historical infertility problems was detected. The ovaries from the two open cows and the mummified foetus of a third one were removed, and two sets of tissue samples were collected. Histopathology analysis revealed the presence of follicular abnormalities. The DNA tests revealed the presence of *Anaplasma marginale*, *Babesia bigemina* and/or *Babesia bovis*. In conclusion, the present work represents the first report of tick-borne pathogens in ovarian tissue samples and a mummified foetus of infertile cows in tropical conditions in Northern Veracruz, Mexico, highlighting the possibility that many reproductive problems in tropical conditions could be caused by tick-borne pathogens.

Key words: Abortion; bovine anaplasmosis; bovine babesiosis; infertility; tropical reproductive diseases

RESUMEN

El objetivo de este estudio fue identificar la presencia de patógenos transmitidos por garrapatas como la causa probable de problemas reproductivos en vacas procedentes de una explotación comercial de doble propósito que viven en condiciones tropicales en el norte de Veracruz, México. Como parte del control reproductivo del rebaño, se realizó ecografía periódicamente y se detectó la presencia de tres vacas abiertas (no preñadas) con historia de infertilidad. Se extrajeron los ovarios de las dos vacas abiertas, así como el feto momificado de una tercera, y se obtuvieron dos conjuntos de muestras de tejido. El análisis histopatológico reveló la presencia de anomalías foliculares. Las pruebas de ADN revelaron la presencia de *Anaplasma marginale*, *Babesia bigemina* y/o *Babesia bovis*. En conclusión, el presente trabajo representa el primer reporte de patógenos transmitidos por garrapatas en muestras de tejido ovárico y un feto momificado de vacas infértiles en condiciones tropicales en el norte de Veracruz, México, destacando la posibilidad de que muchos problemas reproductivos en condiciones tropicales puedan ser causados por patógenos transmitidos por garrapatas.

Palabras clave: Abortos; anaplasmosis bovina; babesiosis bovina; infertilidad; enfermedades reproductivas tropicales

INTRODUCTION

Reproductive diseases represent the main cause of economic losses in dairy and beef cattle (*Bos taurus*) production [19]. Abortions and stillbirths in productive animals are estimated to represent an approximated cost between USD 500 and 900 per case [3, 11]. In general, the main agents that can cause abortive syndromes include viruses (bovine viral diarrhoea, bovine viral rhinotracheitis), bacteria (*Leptospira* spp., *Brucella* spp.) and parasites (*Toxoplasma gondii*, *Neospora caninum*) [12]. In tropical environments, several tick-borne microorganisms have a significant impact on the reproductive health of production animals [5, 10]. On the American Continent, bovine babesiosis (caused by *Babesia bigemina* and *Babesia bovis*) and bovine anaplasmosis (caused by *Anaplasma marginale*), are the two major diseases responsible for production losses of around 100,000 million USD [14]. In Mexico, both tick-borne diseases are endemic. Various serological and molecular studies have shown a prevalence higher than 50%, particularly in the States of Coahuila, Nuevo León, Tamaulipas, and Veracruz [6, 17].

Both groups of pathogens produce fever, which has a negative impact on pregnant animals since hyperthermia can affect early embryo implantation and/or the establishment and development of the placenta. Some historical studies have suggested that these organisms do not have the ability to penetrate the placenta, although there is new evidence that they can infect the foetal internal organs [9].

It is noteworthy that reports of abortions caused by anaplasmosis and babesiosis in bovines are historical, scattered and scarce: *A. marginale* was recorded in stillbirths of Brazil between 1974–1975, whereas *B. bovis* was recorded in an abortion in Australia in 1986 [4, 20]. Experimental trials in South Africa have demonstrated that animals born to females infected with *A. marginale* develop antibodies weeks after birth and, if they were splenectomised, that they become chronic carriers of the pathogen [16]. Serological studies have shown that a high prevalence of *A. marginale* infection is correlated with a high frequency of abortive events. Yet, the first study in which *A. marginale* and *B. bovis* were molecularly identified in abortions was carried out in Brazil between 2018 and 2019 [9].

For Mexico, there are no studies where these tick-borne pathogens have been correlated with mummified fetuses or ovaries from infertile cows. Therefore, the aim of the present study was to identify the presence of tick-borne pathogens in the ovaries from two infertile cows and the internal organs from a mummified foetus of a third one in a region with high prevalence of *A. marginale* and *B. bovis* in the North of Veracruz, Mexico.

MATERIALS AND METHODS

This study was performed in a private dual-purpose cow *Bos taurus* × *Bos indicus* operation in a tropical warm, high-humidity region in northern Mexico (20°57'0"N, 97°24'0"W). The vaccination program against diseases that affected reproduction consisted of: a) Annual application (January) of inactivated virus vaccine against Infectious Bovine Rhinotracheitis (IBR), Bovine Viral Diarrhoea (BVD) biotype 2 – non-cytopathic, Parainfluenza 3 (PI3), Bovine Respiratory Syncytial Virus (RSBV) and bacterin against: *Leptospira interrogans* serovars: canicola, grippotyphosa, icterohaemorrhagiae, pomona and *Leptospira borgpetersenii* serovar hardjo-bovis and, b) Annual application (July) of bacterin against: *Leptospira interrogans* serovars canicola, grippotyphosa, icterohaemorrhagiae, pomona and *Leptospira*

borgpetersenii serovar hardjo-bovis. As part of the reproductive control of the herd, ultrasonography was performed periodically using a CONTEC Color Doppler Ultrasonic Diagnostic Device (CONTEC, CMS1700A, Singapore). All the cows in the herd were evaluated 21 days after calving and did not present any pathologies. At 80 days postpartum, a second reproductive diagnostic was carried out using ultrasonography and again, the diagnosis was free of pathologies and in optimal conditions to start the synchronization protocol Ovsynch. All cows showed oestrus 21 days after being first bred and they were bred two more times. After one oestrous cycle following treatment, the cows were synchronized using oestradiol benzoate and an intravaginal device containing 1.9 grams (g) of progesterone. During this evaluation the presence of three non-pregnant females with historical infertility problems was detected. Of the three cows involved in this research, two of them had a breed composition of 3/8 *Bos indicus* (Gyr) and 5/8 *Bos taurus* (Holstein) while the other cow had 3/8 *Bos indicus* (Gyr) and 5/8 *Bos taurus* (Brown Swiss).

Hormonal treatments were implemented considering that the cause of the reproductive problem was an endocrine disorder, which was corrected in one of them, becoming pregnant. The other two cows remained open and were treated with antibiotics (intrauterine infusion and intramuscularly), considering that the infertility could be of infectious origin. A systemic treatment with antibiotic (oxytetracycline LA, 200.0 milligrams·kilograms⁻¹–mg·kg⁻¹) was carried out and repeated at 72 hours. Additionally, an intrauterine infusion with 2,000 mg of oxytetracycline in 50 mL of physiological saline solution was also performed and was repeated at 72 hours. Fertility did not improve, for which it was decided to implement a combined scheme of hormones and antibiotics. It is important to mention that *Amblyomma mixtum* and *Rhipicephalus microplus* ticks are endemic in this region, as well as the diseases they can transmit (Babesiosis and Anaplasmosis). However, the three cows never presented any signs of diseases caused by these haemoparasites. Additionally, these two cows were placed in an enclosure with a bull of the same race for a period of 65 days to try to get them pregnant; however, at the end of the period, both specimens remained open. After periodic ultrasonography, the development of persistent follicular cysts was observed in one of them (FIG. 1A), and the other cow had developed a corpus luteum (CL) with a very echogenic but small area that had been growing for several weeks and was diagnosed as a persistent CL (FIG. 1B). The third cow, the one that became pregnant, was diagnosed with a mummified foetus.

The ovaries from the two non-pregnant cows were removed, and tissue samples were collected.

In the third cow, the mummified foetus was recovered by c-section (FIG. 1C and 1D), and a total of 30 samples of different organs (brain, lung, cardiac muscle, skeletal muscle, among others) were collected (FIG. 2C.).

Two sets of tissue samples of the mummified foetus (including the ovaries of the two open cows) were collected. one of them was immersed in formaldehyde solution at 5% and sent to the diagnostic laboratory for histopathological diagnose; the other sample set was fixed in 70% ethanol for Deoxyribonucleic acid (DNA) extraction. Histopathological studies were carried out using haematoxylin-eosin (H-E) staining to determine changes in sample tissues.

Genomic DNA was extracted individually from a portion of 25 mg of tissue, using the QIAamp® DNA Mini Kit (QIAGEN, Hilden, Germany) according to the manufacturer's specifications (using the Purification of Total DNA from Animal Tissues Protocol). As an endogenous control of the extraction, a fragment of ≈708 base pairs (bp) of the mitochondrial

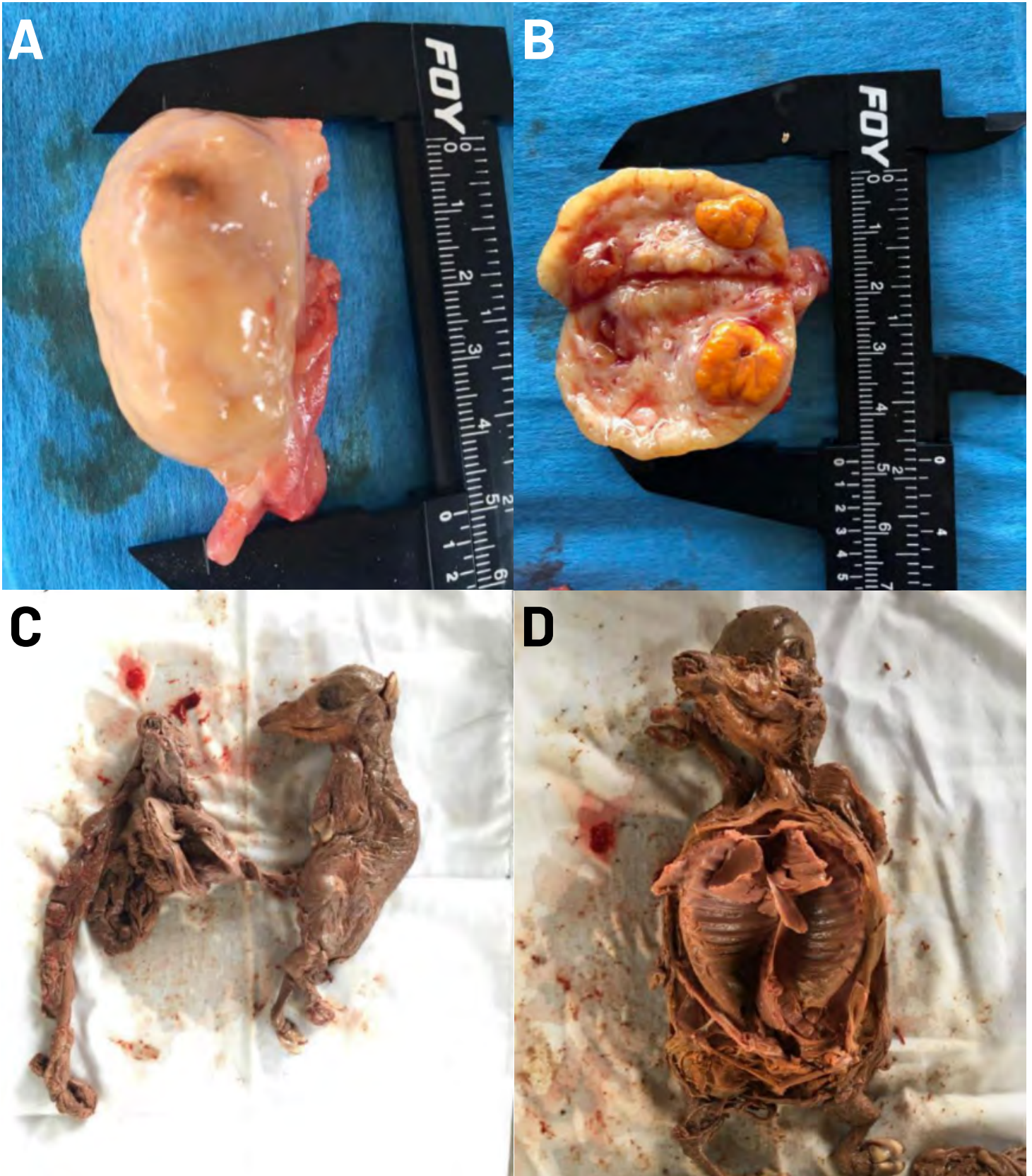


FIGURE 1. Ovaries from adults (A, B) and fetuses (C, D) with anaplasmosis, babesiosis, or both conditions

gene Cytochrome Oxidase Subunit 1 (COI) was amplified, using the primers LC01490 and HCO2198 [7]. For *Ehrlichia/Anaplasma* detection, it was used the primers EHR16SD/EHR16SR, which amplified a fragment of 345 bp of the ribosomal gene 16S rDNA [15].

For *Brucella* DNA detection, conventional polymerase chain reaction probe (PCR) was performed in a Veriti 96-Well Fast Thermal Cycler (ThermoFisher Scientific, 4375305, Massachusetts, USA) using the primers F4/R2, proposed by Romero *et al.* [18], which amplify a 900-bp fragment of the ribosomal 16S-rDNA gene (16S). In the case of *Leptospira* detection, it was amplified a fragment of 400 bp of the 32-kilodalton (Kd) lipoprotein, using the primers Lip32+/Lip32- [21]. Finally, *Babesia/Theileria* were detected using the primers BAB01/BAB02 [2]. The reaction mixture was prepared in a final volume of 25 microliters (μ L) reaction mix, with 12.5 μ L of GoTaq[®] Green Master Mix, 2X Promega Corporation (Madison, WI, USA), 1 μ L of each primer (100 nanograms (ng) each), 10 μ L DNA (~50 ng) and 0.5 μ L nuclease-free water. It was included positive (DNA of *Anaplasma ovis*, *Brucella mellitensis*, *Ehrlichia canis*, *Leptospira borgpetersenii* and *Theileria equi*) and negative (ultrapure water instead of DNA) controls.

The amplification products were subjected to electrophoresis in 2% agarose gel [15] stained with Smartglow. The positive PCR product was sequenced at Macrogen Inc., Korea. The sequence was compared with those of the references deposited in GenBank, using the BLASTn tool as a preliminary confirmation of the presence of bacterial and parasitic sequences. The sequences obtained were deposited in GenBank under accessions numbers MZ798902 for *A. marginale* (16S rDNA) and MZ798903-MZ798904 for *B. bigemina* and *B. bovis* (18S rDNA). This study was approved by the Bioethics Committee of the Facultad de Ciencias Biológicas y Agropecuarias, Campus Tuxpan of the Universidad Veracruzana (UV). Animals were handled according to National Legislation and Ethics (NOM-012-Z00-1993).

RESULTS AND DISCUSSIONS

In the case of the first non-pregnant cow with a history of infertility, the presence of a chronic follicular cyst in one of the ovaries was detected by ultrasonography (FIG. 2A).

After surgical extraction, the presence of a follicular cyst with a thick calcified wall and an accumulation of 14 millilitres (mL) of follicular fluid was confirmed (FIG. 2A), and the other ovary of this cow presented an exaggerated number of growing follicles, which were diagnosed as pathological (FIG. 2B). Histopathological analysis of the samples revealed the following findings: In the case of the non-pregnant cow diagnosed with follicular cyst, an exaggerated population of growing follicles was observed in one ovary, and the histopathological diagnosis was the presence of follicular cysts in the ovary cortex (FIG. 2A) and in the ovary that presented the chronic follicular cyst (FIG. 2B); a surface with a degree of calcification was macroscopically identified, and the tissue continued with a calcification that changed to a yellow colour (FIG. 2C).

Microscopic description indicated a benign cystic tumour with a calcified wall, fragmented and lined by serous-type simple cuboidal epithelium whose nuclei did not show atypia or mitoses and was considered negative for neoplasms (FIG. 2 A-C).

The second non-pregnant cow and with a history of infertility had developed a persistent CL with a highly echogenic area, diagnosed by ultrasonography. After surgical removal, a CL with calcifications was identified. Subsequently, a CL was observed in the ovary that had a calcified membrane, and histopathological analysis described

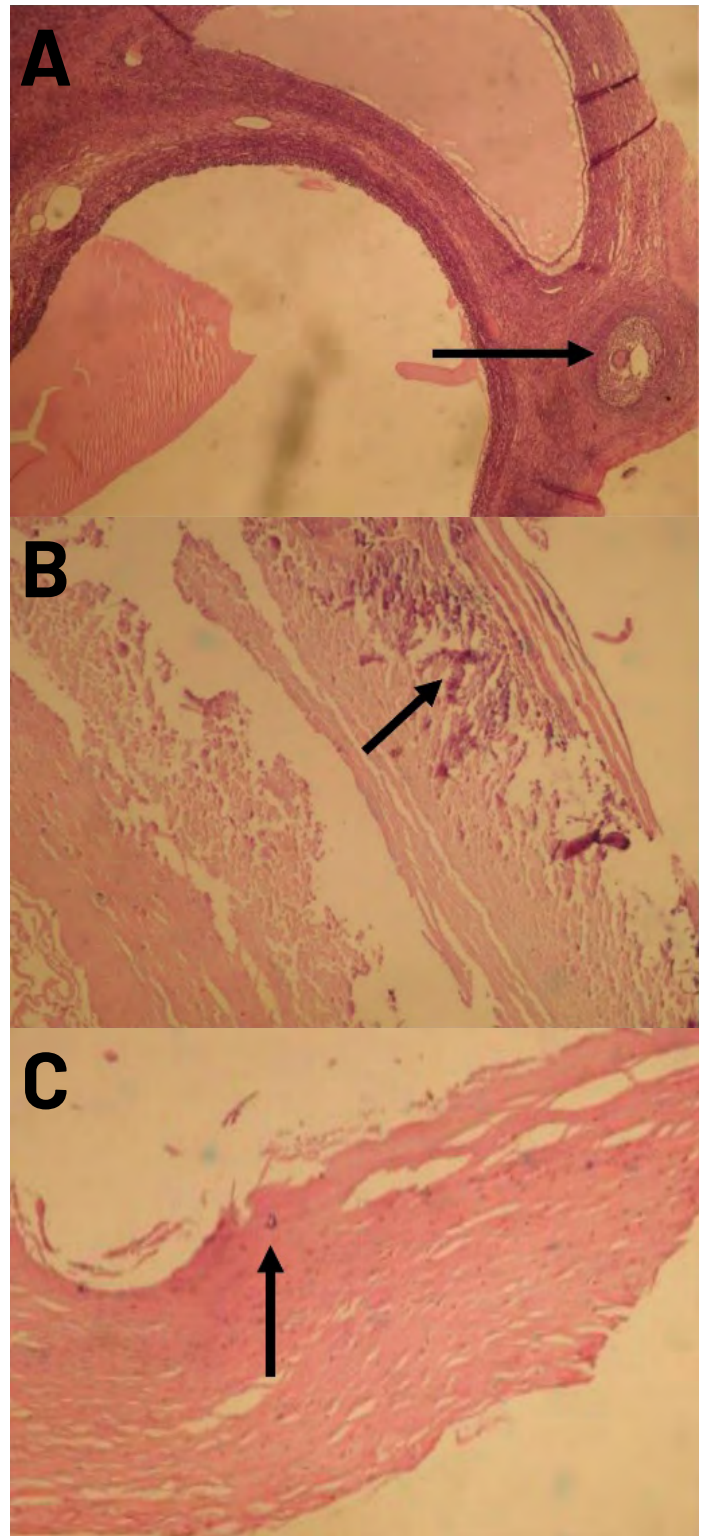


FIGURE 2. Histopathological results: (A) case one (left ovary): small follicular cysts were observed in the ovary cortex (arrow). (B) case one (right ovary) calcification process in the cyst wall (arrow). (C) case two (right ovary) calcification in the cyst wall (arrow)

a haemorrhagic CL of a dark colour with a high content of leukocytes and hemosiderin.

In the third cow, internal organ samples of one mummified embryo were recovered, with different degrees of decomposition (FIG. 1C, 1D). A total of 30 samples of different organs (brain, lung, cardiac muscle, skeletal muscle, among others were analysed). All samples were negative for the presence of *Brucella*, *Ehrlichia*, *Leptospira* and *Toxoplasma* DNA. However, DNA from members of the genus *Anaplasma* and the genus *Babesia* was detected in brain, liver, and spleen from the mummified foetus and in the ovaries of the two open cows (FIG 3).

The sequences generated in this study exhibited a similarity of 99% (450/453 bp) with *A. marginale* [GenBank accession number MN187218] from a *Bos taurus* of Croatia detected in 2018. A similarity of 99% (449/453 bp) was detected with *B. bovis* [MH045761] from *B. taurus* of Mexico, and a 99% (493/496 pb) similarity was found with *B. bigemina* [KP710228] from *B. taurus* of China, detected in 2012.

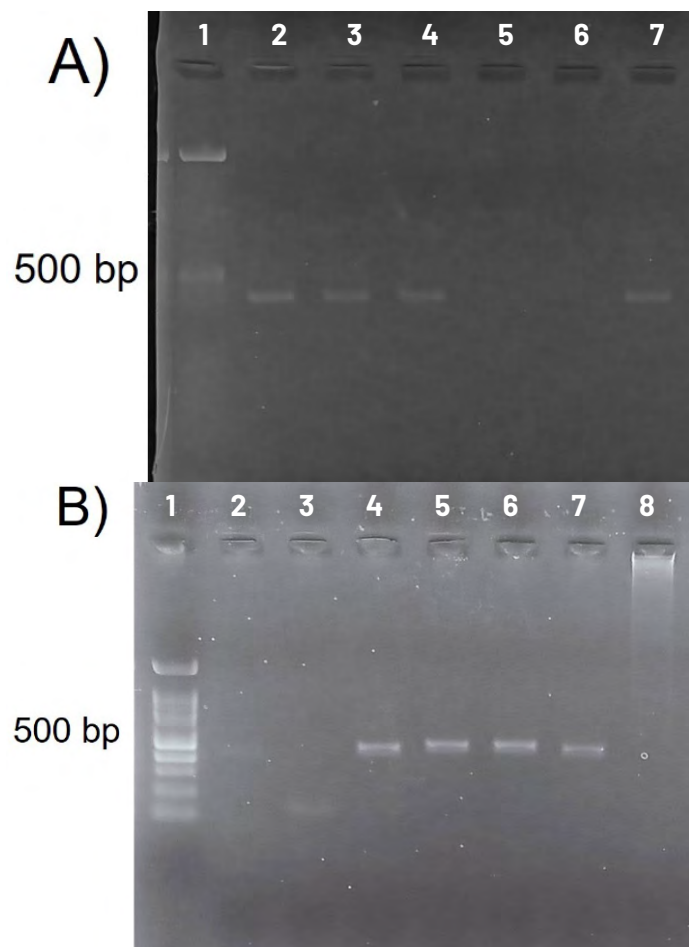


FIGURE 3. Agarose-gel electrophoresis of the PCR products amplified with primers for **A) *Anaplasma*** [Line 1: 100 bp DNA marker ladder; Line 2: Ovary of cow 1; Line 3: Fetal liver; Line 4: Fetal brain; Line 5: Fetal lung; PCR Controls; Line 6: Negative control (nuclease free water without DNA); Line 7: Positive control (DNA of *Anaplasma marginale*); and **B) *Babesia*** [Line 1: 100 bp DNA marker ladder; Line 2: Ovary of cow 2; Line 3: Fetal lung; Line 4: Ovary of cow 2; Line 5: Fetal liver; Line 6: Fetal brain; PCR Controls; Line 7: Positive control (DNA of *Theileria equi*); Line 8: Negative control (nuclease free water without DNA)] detection

Anaplasma marginale was detected in all animals, whereas *B. bovis* and *B. bigemina* were each detected in a single animal. Coinfections with *A. marginale*/*B. bovis* and *A. marginale*/*B. bigemina* were detected in all analysed samples.

This work now constitutes the first record of *A. marginale*, *B. bovis* and *B. bigemina* in samples from abortions and ovaries of animals with infertility problems in Mexico. The present study is in accordance with research carried out in a tropical region of Brazil [9], where the presence of these pathogens was established in samples analysed for bovine abortions. A high prevalence and low genetic diversity of these pathogens was found in Brazil, showing that coinfections with *Anaplasma*/*Babesia* were common, although to date, only the coinfection of *A. marginale*/*B. bovis* has been reported. In contrast, our study now reports the presence of *A. marginale*/*B. bigemina* in Mexican livestock ovaries and a mummified foetus in Veracruz. These findings are not surprising given that both groups of pathogens are transmitted by the same vector, the cattle tick *Rhipicephalus microplus* [13]. According to the histopathological results, it is important to mention that the pathophysiology of these pathogens caused infertility [8]. It is possible that the presence of these pathogens in the ovary triggered a chronic inflammatory process, with infiltration of leukocytes and monocytes and the generation of immunological processes, which could have modified the physiological hormonal secretion, preventing a correct reproductive cycle [1]. In addition, it is relevant to mention that it would have been extremely difficult to make the diagnosis in the field, especially because these pathogens are not considered reproductive pathogens. However, based on these findings, they can be considered as pathogens that can affect reproduction in bovine females, especially in endemic areas of bovine anaplasmosis and babesiosis [6, 17].

CONCLUSIONS

Tick-borne pathogens represent one of the most important challenges in livestock production worldwide. In Mexico, both bovine anaplasmosis and bovine babesiosis cause severe economic losses due to subclinical infections that interfere with weight gain and milk production in animals in the productive stage. Furthermore, both diseases generate haemolytic anaemia, which can compromise the life of the host in acute stages. However, these pathogens are not commonly correlated with infertility and/or abortion problems.

The question arises as to how to make the diagnosis when these pathogens are found in the ovary or in the foetus, and it is therefore recommended to continue with more investigations to resolve many of the doubts that have arisen as a result of this investigation.

The findings of the present work highlight the possibility that many reproductive problems could be caused by tick-borne pathogens, stressing the necessity to implement differential diagnoses of bovine anaplasmosis and babesiosis in animals that present reproductive problems in endemic areas of both diseases in the Mexican tropics.

Animal ethics

This study was approved by the Bioethics Committee of the Facultad de Ciencias Biológicas y Agropecuarias, Campus Tuxpan of the Universidad Veracruzana (UV) (Animals were handled according to National Legislation and Ethics (NOM-012-ZOO-1993).

ACKNOWLEDGMENTS

We thank the cattle producer and his staff for their collaboration to get this study completed.

Financial support

The project was partially financed by UNAM-PAPIIT IG201221.

Conflicts of interest

The authors certify that they have no affiliations with or involvement in any organization or entity with any financial interest, nonfinancial interest in the subject matter or materials discussed in this manuscript

Code availability

The sequences obtained were deposited in GenBank under accessions numbers MZ798902 for *A. marginale* (16S rDNA) and MZ798903-MZ798904 for *B. bigemina* and *B. bovis* (18S rDNA).

Ethical statement

The authors confirm that the ethical policies of the journal, as noted on the journal's author guidelines page, have been adhered to. This project was approved by the Bioethics and Animal Welfare Committee of the University of Veracruz, School of Biological and Agricultural Sciences, Tuxpan de Rodríguez Cano, Veracruz, Mexico.

BIBLIOGRAPHICS REFERENCES

- [1] ALLEN, G.P. The pregnancy that doesn't stay—lessons from 25 years of observation. **Vet. J.** 153: 239–244. 1997. <https://doi.org/d8wmkp>.
- [2] ALMEIDA, A.P.; MARCILI, A.; LEITE, R.C.; NIERI-BASTOS, F.A.; DOMINGUES, L.N.; MARTINS, J.R.; LABRUNA, M.B. *Coxiella* symbiont in the tick *Ornithodoros rostratus* (Acari: argasidae). **Ticks. Tick. Dis.** 3: 203–206. 2021. <https://doi.org/f37cnr>.
- [3] CLOTHIER, G.; WAPENAAR, W.; KENNY, E.; WINDHAM, E. Farmers' and veterinary surgeons' knowledge, perceptions and attitudes towards cattle abortion investigations in the UK. **Vet. Rec. Open.** 187: 447. 2020. <https://doi.org/grd9zx>.
- [4] CORREA, W.M.; CORREA, C.N.; GOTTSCHALK, A.F. Bovine abortion associated with *Anaplasma marginale*. **Can. J. Comp. Med.** 42: 227–228. 1978.
- [5] DUGAT, T.; HACIANE, D.; DURAND, B.; LAGRÉE, A.C.; HADDAD, N.; BOULOUIS, H.J. Identification of a Potential Marker of *Anaplasma phagocytophilum* Associated with Cattle Abortion. **Transbound. Emerg. Dis.** 64: e1–e3. 2017. <https://doi.org/gbwj38>.
- [6] ESTEVE-GASENT, M.D.; RODRÍGUEZ-VIVAS, R.I.; MEDINA, R.F.; ELLIS, D.; SCHWARTZ, A.; CORTÉS-GARCIA, B.; HUNT, C.; TIETJEN, M.; BONILLA, D.; THOMAS, D.; LOGAN, L.L.; HASEL, H.; ALVAREZ-MARTÍNEZ, J.A.; HERNÁNDEZ-ESCARREÑO, J.J.; MOSQUEDA-GUALITO, J.; ALONSO-DÍAZ, M.A.; ROSARIO-CRUZ, R.; SOBERANES-CÉSPEDES, N.; MERINO-CHARREZ, O.; HOWARD, T.; PÉREZ DE LEÓN, A. A. Research on Integrated Management for Cattle Fever Ticks and Bovine Babesiosis in the United States and Mexico: Current Status and Opportunities for Binational Coordination. **Pathog.** 9: 871. 2020 <https://doi.org/f7fc>.
- [7] FOLMER, O.; BLACK, M.; HOEH, W.; LUTZ, R.; VRIJENHOEK, R. DNA primers for amplification of mitochondrial cytochrome c oxidase subunit I from diverse metazoan invertebrates. **Mol. Marine. Biol. Biotechnol.** 3: 294–299. 1994.
- [8] GIVENS, M.D. A clinical, evidence-based approach to infectious causes of infertility in beef cattle. **Theriogenol.** 66: 648–654. 2006. <https://doi.org/bmvbbp>.
- [9] HENKER, L.C.; LORENZETT, M.P.; FAGUNDES-MOREIRA, R.; DALTO, A.; SONNE, L.; DRIEMEIER, D.; SOARES, J.F.; PAVARINI, S.P. Bovine abortion, stillbirth and neonatal death associated with *Babesia bovis* and *Anaplasma* spp. infections in southern Brazil. **Ticks. Tick. Dis.** 11: 101443. 2020. <https://doi.org/jzcz>.
- [10] HURTADO, O.J.B.; GIRALDO-RÍOS, C. Economic and health impact of the ticks in production animals. In: Abubakar, M.; Perera, P.K. (Eds.). **Ticks and Tick-Borne Pathogens**. IntechOpen 2019, London, UK. Pp. 1–19. 2019.
- [11] SARANGI, L.N.; THARANI, N.; POLAPALLY, S.; RANA, S.K.; THODANGALA, N.; BAHEKAR, V.S.; PRASAD, A.; CHANDRASEKHAR-REDDY, R.V.; SURENDRA, K.S.N.L.; GONUGUNTLA, H.N.; PONNANNA, N.M.; SHARMA, G.K. Infectious bovine abortions: observations from an organized dairy herd. **Braz. J. Microbiol.** 52: 439–448. 2021. <https://doi.org/ghvx4g>.
- [12] LUCCHESI, L.; BENKIRANE, A.; HAKIMI, I.; EL IDRISSE, A.; NATALE, A. Seroprevalence study of the main causes of abortion in dairy cattle in Morocco. **Vet. Ital.** 52: 13–19. 2016. <https://doi.org/jzcz>.
- [13] MAKENOV, M.T.; TOURE, A.H.; KORNEEV, M.G.; SACKO, N.; PORSHAKOV, A.M.; YAKOVLEV, S.A.; RADYUK, E.V.; ZAKHAROV, K.S.; SHIPOVALOV, A.V.; BOUMBALY, S.; ZHURENKOVA, O.B.; GRIGOREVA, Y.E.; MOROZKIN, E.S.; FYODOROVA, M.V.; BOIRO, M.Y.; KARAN, L.S. *Rhipicephalus microplus* and its vector-borne haemoparasites in Guinea: further species expansion in West Africa. **Parasitol. Res.** 120: 1563–1570. 2021. <https://doi.org/gjmfyz>.
- [14] MCCALLON, B.R. Prevalence and economic aspects and anaplasmosis: In: **Proceedings of the Sixth National Anaplasmosis Conference**. Las Vegas, March 19 and 20, 1973, Nevada, USA. Stillwater, Oklahoma: Heritage Press. Pp. 1–3. 1973.
- [15] MURPHY, D.S.; LEE, X.; LARSON, S.R.; JOHNSON, D.K.; LOO, T.; PASKEWITZ, S.M. Prevalence and distribution of human and tick infections with the *Ehrlichia muris* like agent and *Anaplasma phagocytophilum* in Wisconsin, 2009–2015. **Vector Borne Zoon. Dis.** 17: 229–236. 2017.
- [16] POTGIETER, F.T.; VAN RENSBURG, L. The persistence of colostral *Anaplasma* antibodies and incidence of in utero transmission of *Anaplasma* infections in calves under laboratory conditions. **Onderstepoort. J. Vet. Res.** 54: 557–560. 1987.
- [17] RODRÍGUEZ, S.D.; GARCÍA, O.M.A.; JIMÉNEZ, O.R.; VEGA Y MURGUÍA, C.A. Molecular epidemiology of bovine anaplasmosis with a particular focus in Mexico. **Infect. Genet. Evol.** 9: 1092–1101. 2009. <https://doi.org/dv76js>.
- [18] ROMERO, C.; PARDO, M.; GRILLO, M.J.; DÍAZ, R.; BLASCO, J.M.; LÓPEZ-GOÑI, I. Evaluation of PCR and indirect enzyme-linked immunosorbent assay on milk samples for diagnosis of brucellosis in dairy cattle. **J. Clin. Microbiol.** 33: 3198–3200. 1995. <https://doi.org/jzcz>.

- [19] SUBEKTI, D.T.; FATMAWATI, M.; KHOIRIYAH, A.; PRAMESTHI, A.; FONG, S.; DESEM, M.I.; AZMI, Z.; KUSUMANINGTYAS, E.; ENDRAWATI, D.; PURWANTO, E.S. Seroprevalence of Seven Reproductive Diseases in Beef and Dairy Cows from Three Provinces in Indonesia. **Vet. Med. Int.** 2021(2): e6492289. 2021. <https://doi.org/jzc5>.
- [20] TRUEMAN, K.F.; MCLENNAN, M.W. Bovine abortion due to prenatal *Babesia bovis* infection. **Aus. Vet. J.** 64: 63. 1987.
- [21] VITAL-BRAZIL, J.M.; BALASSIANO, I.T.; OLIVEIRA, F.S.; COSTA, A.D.; HILLEN, L.; PEREIRA, M.M. Multiplex PCR-based detection of *Leptospira* in environmental water samples obtained from a slum settlement. **Mem. Inst. Oswaldo. Cruz.** 105: 353–355. 2010. <https://doi.org/dn8bfp>.